

# Heterozygous Ile453Val codon mutation in exon 7, homozygous single nucleotide polymorphisms in intron 2 and 5 of *cathepsin C* are associated with Haim-Munk syndrome

Nalini Aswath<sup>1</sup>, Bhuminathan Swamikannu<sup>2</sup>, Sankar Narayanan Ramakrishnan<sup>1</sup>, Rajendran Shanmugam<sup>3</sup>, Jayakar Thomas<sup>4</sup>, Arvind Ramanathan<sup>5</sup>

<sup>1</sup>Department of Oral Medicine and Radiology, Sree Balaji Dental College and Hospital, Bharath University, Chennai, Tamil Nadu, India

<sup>2</sup>Department of Prosthodontics, Sree Balaji Dental College and Hospital, Bharath University, Chennai, Tamil Nadu, India

<sup>3</sup>Department of Medicine, Sree Balaji Medical College and Hospital, Bharath University, Chennai, Tamil Nadu, India

<sup>4</sup>Department of Dermatology, Sree Balaji Medical College and Hospital, Bharath University, Chennai, Tamil Nadu, India

<sup>5</sup>Human Genetics Laboratory, Central Research Facility, Sree Balaji Medical and Dental College and Hospital, Bharath University, Chennai, Tamil Nadu, India

**Correspondence:** Dr. Arvind Ramanathan  
Email: drarvindram@yahoo.co.in

## ABSTRACT

**Objective:** In the present study, we have investigated the genetic status of *CTSC* gene in a HMS subject, who along with her parents belonged to non-Jewish South Indian Dravidian community. **Materials and Methods:** Genomic deoxyribonucleic acid isolated from the peripheral blood of the subject was amplified with *CTSC* exon specific primers and were analyzed by direct sequencing. **Results:** Sequencing analysis identified Ile453Val mutation within exon 7 of *CTSC* gene in heterozygous condition, and two single nucleotide polymorphisms (SNPs) within intron 2 and 5 in homozygous condition. **Conclusion:** The present study has identified for the first time the association of Ile453Val mutation within exon 7 and the two SNPs in a subject with HMS.

**Key words:** *Cathepsin C* mutation, Hain-Munk syndrome, Hain-Munk syndrome in India, single nucleotide polymorphism in Hain-Munk syndrome

## INTRODUCTION

Hain-Munk syndrome (HMS) (OMIM #245010) is an extremely rare form of autosomal recessive disorder,<sup>[1,2]</sup> which along with Papillon-Lefevre syndrome (PLS) (OMIM #245,000)<sup>[3]</sup> is classified as type IV palmoplantar keratoderma (PPK).<sup>[4]</sup> PPKs are a heterogeneous group of disorders, which are characterized by abnormal thickening of the palms

and sole and are classified into focal PPK, diffuse PPK, punctuate PPK and palmoplantar ectodermal dysplasia based on clinical sites of lesions, associated lesions and histopathologic findings.<sup>[5]</sup>

Also called as “Cochin Jewish disorder,” HMS was first reported by Haim and Munk in 1965 among members of a small Jewish community from Cochin in India. Beyond its occurrence in the Jewish members

**How to cite this article:** Aswath N, Swamikannu B, Ramakrishnan SN, Shanmugam R, Thomas J, Ramanathan A. Heterozygous Ile453Val codon mutation in exon 7, homozygous single nucleotide polymorphisms in intron 2 and 5 of *cathepsin C* are associated with Haim-Munk syndrome. *Eur J Dent* 2014;8:79-84.

Copyright © 2014 Dental Investigations Society.

DOI: 10.4103/1305-7456.126250

of Cochin, HMS has not been reported in other population. However, PLS has been found to have a world-wide prevalence with incidence of 1-4 cases per million of the general population.<sup>[6]</sup> The clinical symptoms of HMS includes congenital palmoplantar keratosis, severe early onset periodontitis, aggressive periodontitis (AgP) accompanied by tooth loss, recurrent pyogenic cutaneous infections, atrophic nail deformities, acroosteolysis, arachnodactyly, radiographic deformity of the fingers and pes planus. Though the palmoplantar hyperkeratotic lesions and aggressive periodontal condition are also seen in PLS, the presence of nail deformities, arachnodactyly, acroosteolysis and pes planus distinguishes HMS from PLS.<sup>[6-8]</sup>

*Cathepsin C (CTSC)* is a lysosomal cysteine proteinase coding gene,<sup>[9,10]</sup> which encodes for *CTSC* protein that plays a major role in the activation of granule serine proteases, granzymes A and B, tryptase and chymase, and cathepsin G and elastase from immune cells.<sup>[11]</sup> High levels *CTSC* expression has been observed in polymorphonuclear leukocytes, alveolar macrophages, plantar, palmar and gingival epithelium.<sup>[6]</sup> Hence disruption in the expression or function of *CTSC* caused by mutations may be expected to produce clinical manifestations. Indeed, genetic analysis of *CTSC* gene in HMS subjects has identified mutations in exon 1 (c. 145C → T),<sup>[8]</sup> exon 4 (c. 587T → C)<sup>[12]</sup> and exon 6 (c. 2127A → G).<sup>[1]</sup> Since mutation within *CTSC* has also been reported in PLS condition, both HMS and PLS are described as allelic variants of *CTSC*.<sup>[1,8]</sup> Studies so far have reported the occurrence of this mutation in HMS and PLS subjects with consanguineous parentage in a majority of cases.<sup>[6,8]</sup> However, more recently PLS has been reported in subjects born to non-consanguineous parents as well.<sup>[6]</sup> In the present study, we have investigated the genetic status of *CTSC* gene in a patient with clinical symptoms of HMS to: (1) Confirm that the subject indeed had a mutation in *CTSC* gene, which is indicative of HMS and (2) to find out the mutant region with the *CTSC* gene in the subject, especially since neither the subject nor her parents were from the Cochin Jewish background, but belonged to the South Indian Dravidian race.

## MATERIALS AND METHODS

### Patient selection

A 23-year-old subject who reported to the institute for evaluation of oral condition was provisionally diagnosed with HMS associated with AgP. After obtaining informed consent from the subject and

accompanying parent, 1 ml of peripheral blood sample was obtained for genetic investigation. The study was cleared by the institutional ethics committee.

### Genomic deoxyribonucleic acid extraction, polymerase chain reaction and direct sequencing

A total volume of 0.2 ml of the whole blood sample was processed for DNA extraction with GenElute blood genomic DNA kit (cat #NA2000, Sigma-Aldrich, St. Louis, MO, USA). 100 ng of the extracted genomic DNA was amplified with independent set of primers flanking each of exon 1-7 [Table 1]. An universal amplification program was used to amplify the exons as follows: after an initial denaturation at 94°C for 2 min, the exons were amplified for 35 cycles with denaturation at 95°C for 45 s, annealing at 55°C for 45 s and extension at 72°C for 1 min, with a ramp of 1°/s, which was followed by a final extension at 72°C for 5 min. The amplified regions of each of the exon was run in a 1.2% agarose gel and eluted with GenElute DNA gel elution kit (Sigma Aldrich, Cat# NA1111). A 10 ng aliquot of the eluted PCR amplicons was subsequently subjected to direct sequencing with either forward or reverse PCR primers to identify for the presence of mutations.

## RESULTS

### Clinical evaluation

A 23-year-old South Indian female from a consanguineous family reported with complaints of edentulism and recurrent skin infections that had aggravated since the age of 5 years. Clinical investigation revealed loss of all her primary teeth between the age of 3 and 4 years and premature

**Table 1: Primer sequences that were used to amplify exons 1-7 of *CTSC* gene**

ID	Primer sequence
HMSe1f	caagtcgccgtttcagag
HMSe1r	aagggcagaaaggacgac
HMSe2f	tcactaggcagactgtgctc
HMSe2r	ggaagagtgtgtcaattcc
HMSe3f	gagagccatgaaatggac
HMSe3r	accaaactgacaacacctc
HMSe4f	caggctgttaggctattg
HMSe4r	agcaacactggtaggactgc
HMSe5f	aaacagggtgctctgggtc
HMSe5r	gccattccatctaggatc
HMSe6f	aggcttcagatgtctctgg
HMSe6r	ttccccgccataaatag
HMSe7f	ctaaggggtaaccatgtgtg
HMSe7r	gcttctgagattgctgctg

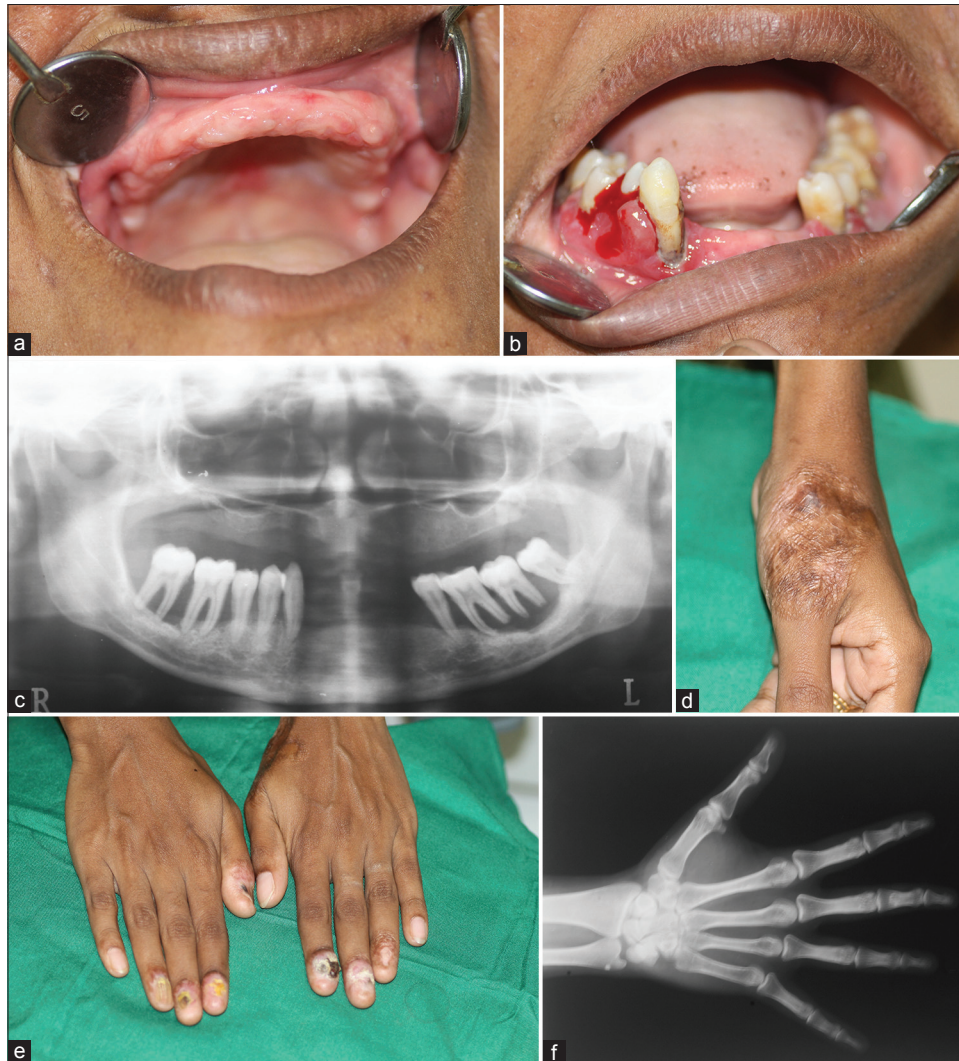
*CTSC: Cathepsin C*

shedding of permanent teeth since the age of 15 years. Intraoral examination showed severe AgP, which was associated with a complete edentulous maxilla, partially edentulous mandible with grade III mobility of mandibular first and second molars [Figure 1a and b]. Orthopantomograph confirmed the clinical observation of AgP, which showed a complete edentulous maxilla, partially edentulous mandible associated with generalized loss of alveolar bone [Figure 1c]. Hyperkeratotic psoriasiform lesions on an erythematous background were present on the dorsal surface of the hands and feet [Figure 1d], which were confirmed by biopsy (data not shown). Besides, nail abnormalities in the form of onychogryphosis were also present, but was clinically pronounced only in the fingers of upper limb [Figure 1e]. Radiograph of the wrist and palm region did not exhibit arachnodactyly [Figure 1f].

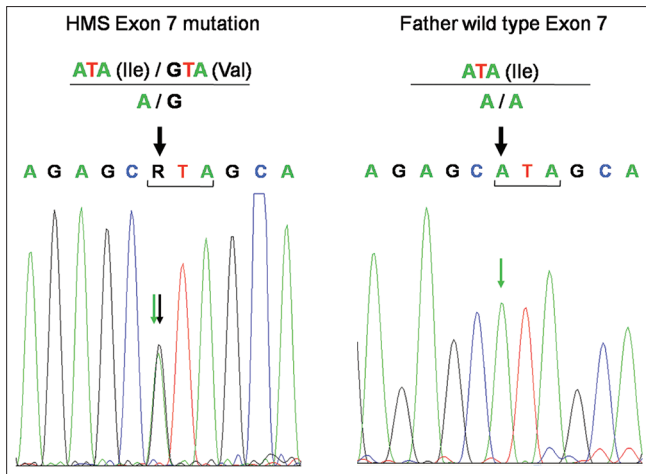
Laboratory investigations for complete blood count, erythrocytic sedimentation rate, serum electrolytes, serum alkaline phosphatase, liver function tests and total bilirubin were found to be normal (data not shown).

#### Genetic analysis of *CTSC*

The longest isoform of *CTSC* consists of seven exons, of which mutation in exons 1, 4 and 6 have been reported to be associated with HMS.<sup>[1,8,12]</sup> In order to examine the genetic status of *CTSC* gene in the HMS subject, the genomic DNA isolated from peripheral blood sample was amplified with intronic primers that flanked each of the seven exons from 50 bp to 100 bp away from splice acceptor and donor sites and subjected to direct sequencing. Sequence analysis identified a single heterozygous point mutation within exon 7 of *CTSC* that caused substitution of the codon



**Figure 1:** Clinical images of Hain-Munk syndrome in the subject. (a) edentulous maxilla; (b) partially edentulous mandible with aggressive periodontitis; (c) orthopantomogram of maxilla and mandible; (d) healed psoriasiform skin lesion; (e) onychogryphosis of fingers of upper limb; (f) radiograph of wrist and palm



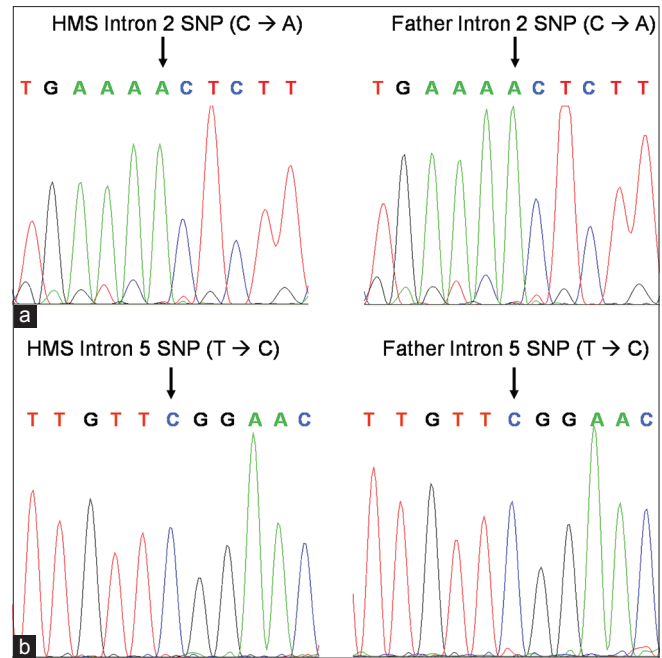
**Figure 2:** Chromatogram of genotype of the mutant sequence of exon 7 of cathepsin C gene. The wild type base, A (indicated by a green arrow) and the mutant base, G (indicated by a black arrow) occur in heterozygous condition in the Hain-Munk syndrome subject, but not in the subject's father

at position 453 from ATA to GTA with a resultant change in the encoded amino acid from isoleucine to valine (Ile453Val) [Figure 2]. Further analysis of the intronic regions that were co-amplified along with each of the seven exon identified single nucleotide polymorphisms (SNPs) within intron 2 at position g. 88068052C > A [Figure 3a] and intron 5 at position g. 88033661T > C [Figure 3b] in homozygous condition.

To investigate the pattern of inheritance of the exon 7 mutation and the intron 2 and 5 SNPs, the genomic copy of the subject's father, who is the lone surviving parent was analyzed by direct sequencing. Sequence comparison identified no mutation within the exon 7, which clearly indicated that the mutant allele was not inherited from the subject's father. However the intron 2 and 5 SNPs were found to occur in homozygous condition. The homozygous occurrence of intron 2 and 5 SNPs in both the subject and that of her father confirmed consanguineous parentage.

## DISCUSSION

In the present study, we have reported a case of HMS, which was diagnosed based on the clinical observation of early onset destructive periodontitis, recurrent pyogenic skin infections, nail deformities and hyperkeratotic lesions on the dorsal surface of the limbs. Though the periodontal pathology and skin infections are also observed in PLS,<sup>[12]</sup> the condition was diagnosed as HMS based on the specific occurrence of nail deformities and severity of hyperkeratotic skin lesions. The subject, however, did not present other cardinal features of HMS like the palmoplantar keratosis, pes planus,



**Figure 3:** Chromatogram of genotypes of the single nucleotide polymorphisms (SNPs) in intron 2 and intron 5. (a) SNP in intron 2 at position g.88068052C > A (indicated by a black downward arrow); (b) SNP in intron 5 at position g.88033661T > C (indicated by a black downward arrow). Note that both SNPs occurred in homozygous condition in the Hain-Munk syndrome patient and the father

arachnodactyly, acroosteolysis and radiographic deformity of fingers and hence distinguished the present condition from that of other reported cases.

Since genetic mutations in the *CTSC* gene have been reported to occur in HMS subjects, we sought to investigate the status of *CTSC* gene mutation in the above subject by direct sequencing of all seven coding exons of *CTSC* along with at least 50bp of corresponding intronic regions. Sequence analysis revealed a single heterozygous point mutation in exon 7, which resulted in the substitution of encoded amino acid, isoleucine by valine in the mutant allele (Ile453Val). Though the mutation event involved substitution between two nonpolar aliphatic (hydrophobic) amino acids, the Ile453Val mutation has earlier been shown to cause a reduction in the protease activity of *CTSC* protein.<sup>[13]</sup> The Ile453Val mutation, however, was not identified in the subject's father. This observation is in contrast to those reported by Rai *et al.*<sup>[8]</sup> and Hart *et al.*<sup>[1]</sup> in HMS, wherein the subjects were found to be carriers of mutations in either exon 1 or 6 of *CTSC* in homozygous condition when their respective parents carried the same mutation in heterozygous condition. Besides neither the parents nor sibs of the affected subjects in the above studies, who were heterozygous for the mutant and wild type alleles were known to manifest any of the clinically

identifiable HMS or other PPK conditions. Hence, whether the occurrence of Ile453Val *CTSC* mutation in heterozygous condition suffices the development of HMS symptoms or it requires compound mutations with involvement of other genes becomes essential to be investigated. It is very likely that the HMS subject of the present study harbors compound mutations in other genes, which in the presence of heterozygous *CTSC* Ile453Val mutation may have caused the manifestation of the HMS symptoms. This is likely because, *CTSC* Ile453Val mutation has also been reported in non-syndromic AgP,<sup>[13]</sup> where in the only known clinical manifestation appears to be early tooth loss. It may be noted that the HMS subject of the present study carried a few of HMS symptoms in addition to AgP with tooth loss.

Analysis of the associated intronic regions of the seven exons of *CTSC* in the HMS subject and the lone surviving parent also identified SNPs within intron 2 (g. 88068052C > A) and intron 5 (g. 88033661T > C). According to the SNP database of National Center for Biological Information, the SNP within intron 2 identified in the present study has earlier been documented as rs217076 while the SNP within intron 5 is a novel finding. Both SNPs nevertheless occurred in homozygous condition in the HMS subject and the subject's father. These findings strongly suggest that the parents of the affected subject were in fact consanguineous. Since HMS has been reported in the probands of consanguineous parents, it is possible that the Ile453Val mutant allele might have been inherited from the mother. However, from discussions with the HMS subject's father, it was found that the mother had not exhibited any of the clinical symptoms of HMS, including the AgP condition, which is the most obvious and easily identifiable even by non-clinicians. This leads to the suggestion that the subject's mother may not have had the Ile453Val mutation while it occurred in the HMS subject as a sporadic event. Such subject specific sporadic (non-inherited) mutation has been described in exon 2 (c. 203T → G) of *CTSC* gene in PLS subjects alone, where in their respective parents were found to carry wild type base (c. 203T/T).<sup>[6]</sup>

In the present scenario with available clinical and genetic data, the reported condition may be regarded as a non-familial and milder form of HMS as, (1) the subject carried the clinical features of HMS that distinguished it from PLS, (2) the surviving father is disease free while the subject's deceased mother was not known to have carried any of HMS

symptoms, (3) most of other symptoms of HMS as has been elaborated by Hart *et al.* were not observable in the subject and (4) the Ile453Val mutation occurred in heterozygous condition in the subject. However, it remains to be determined whether the co-occurrence of skin lesions and nail deformities alone with AgP is sufficient to consider the condition as HMS. This may be addressed by further clinical and genetic investigations on HMS subjects with defined lineage and generation of consanguineous parents as the severity of symptoms is likely to vary among the HMS subjects born to different generations of consanguineous parents due to the cumulative effect of detrimental mutations.

## CONCLUSIONS

Taken together, the findings of the present study provides clinically significant data as the Ile453Val mutation in exon 7, rs3888798 in intron 2 and a novel SNP in intron 5 have been observed in a compound manner in *CTSC* gene for the first time in a HMS subject. Hence the findings may be used as a lead to further studies on HMS to clinically describe and classify the occurrence of the symptoms in combination with genetic status of *CTSC* gene into mild, moderate and severe forms of HMS.

## ACKNOWLEDGMENT

The authors wish to thank the Central Research Funding Authority of Sree Balaji Medical and Dental College and Hospital, Bharath University, Chennai - 600 100, for providing financial support to conduct the research work.

## REFERENCES

- Hart TC, Hart PS, Michalec MD, Zhang Y, Firatli E, Van Dyke TE, *et al.* Haim-Munk syndrome and Papillon-Lefèvre syndrome are allelic mutations in cathepsin C. *J Med Genet* 2000;37:88-94.
- Pahwa P, Lamba AK, Faraz F, Tandon S. Haim-Munk syndrome. *J Indian Soc Periodontol* 2010;14:201-3.
- Hacham-Zadeh S, Schaap T, Cohen MM. A genetic analysis of the Papillon-Lefèvre syndrome in a Jewish family from Cochin. *Am J Med Genet* 1978;2:153-7.
- Stevens HP, Kelsell DP, Bryant SP, Bishop DT, Spurr NK, Weissenbach J, *et al.* Linkage of an American pedigree with palmoplantar keratoderma and malignancy (palmoplantar ectodermal dysplasia type III) to 17q24. Literature survey and proposed updated classification of the keratodermas. *Arch Dermatol* 1996;132:640-51.
- Erciyas K, Inaloz S, Erciyas AF. Periodontal manifestations in a patient with Haim-Munk syndrome. *Eur J Dent* 2010;4:338-40.
- Romero-Quintana JG, Frías-Castro LO, Arámbula-Meraz E, Aguilar-Medina M, Dueñas-Arias JE, Melchor-Soto JD, *et al.* Identification of novel mutation in cathepsin C gene causing Papillon-Lefèvre Syndrome in Mexican patients. *BMC Med Genet* 2013;14:7.
- Janjua SA, Iftikhar N, Hussain I, Khachemoune A. Dermatologic,

- periodontal, and skeletal manifestations of Haim-Munk syndrome in two siblings. *J Am Acad Dermatol* 2008;58:339-44.
8. Rai R, Thiagarajan S, Mohandas S, Natarajan K, Shanmuga Sekar C, Ramalingam S. Haim Munk syndrome and Papillon Lefevre syndrome – Allelic mutations in cathepsin C with variation in phenotype. *Int J Dermatol* 2010;49:541-3.
  9. Conus S, Simon HU. Cathepsins and their involvement in immune responses. *Swiss Med Wkly* 2010;140:w13042.
  10. Nakagawa TY, Rudensky AY. The role of lysosomal proteinases in MHC class II-mediated antigen processing and presentation. *Immunol Rev* 1999;172:121-9.
  11. Reiser J, Adair B, Reinheckel T. Specialized roles for cysteine cathepsins in health and disease. *J Clin Invest* 2010;120:3421-31.
  12. Cury VF, Gomez RS, Costa JE, Friedman E, Boson W, De Marco L. A homozygous cathepsin C mutation associated with Haim-Munk syndrome. *Br J Dermatol* 2005;152:353-6.
  13. Noack B, Görgens H, Hempel U, Fanghänel J, Hoffmann T, Ziegler A, *et al.* Cathepsin C gene variants in aggressive periodontitis. *J Dent Res* 2008;87:958-63.

Access this article online	
<b>Quick Response Code:</b> 	<b>Website:</b> <a href="http://www.eurjdent.com">www.eurjdent.com</a>
<b>Source of Support:</b> Nil. <b>Conflict of Interest:</b> None declared	